



PATIENT PRESENTING CLINICAL SIGNS

Jerry Altshuler

History: History of gallop rhythm and elevated ProBNP (429 last year). Arrhythmia noted x ~ 2 years. History diabetes - in remission, not on medications. Echocardiogram prior to anesthesia for dental procedure.

SPECIES

Feline

ELECTROCARDIOGRAPHIC FINDINGS *Note: Single lead ECGs are evaluated as a rhythm strip. Morphology/MEA cannot be definitively commented on.

BREED

DSH

A single lead ECG is available; 25mm/s, 20mm/mV. The underlying rhythm is sinus in origin with an average heart rate of 200bpm. P for every QRS complex and vice versa. P and QRS morphologies are positive. Frequent isolated VPCs are seen throughout with brief periods of bigeminy. VPCs are monomorphic, singles only. No supraventricular beats, pauses or other dysrhythmias observed.

SEX

Male Neutered

ECG diagnosis: Normal sinus tachycardia with frequent isolated VPCs and periods of bigeminy.

AGE

14 years

ECHOCARDIOGRAM FINDINGS

2D, m-mode, color flow and Doppler imaging is available.

WEIGHT

18lbs

Left ventricle: The LV diameter is normal with adequate myocardial function. The LV wall thicknesses are normal with regions of asymmetry. There is a diffusely hyperechoic endocardium consistent with fibrosis. The papillary muscles are remodeled and hyperechoic. The endocardium appears remodeled.

Left atrium: The left atrium and auricle are markedly dilated with subtle spontaneous contrast. No obvious thrombi seen.

Mitral valve: The mitral valve is normal in structure and mobility. No obvious systolic anterior motion is seen. No MR.

Aortic valve/Aorta: The aortic valve is normal in morphology and mobility. Normal aortic outflow velocity; laminar flow. No aortic insufficiency.

Right ventricle: Mild right ventricular dilation.

Right atrium: The right atrium is mildly dilated.

Tricuspid valve: The tricuspid valve appears normal with no tricuspid regurgitation.

Pulmonic valve/Pulmonary artery: The pulmonic valve is normal in morphology and mobility. No pulmonic insufficiency. Normal RVOT velocity; laminar flow.

Pericardium/other: Small volume pericardial and pleural effusion noted. No obvious cardiac masses.

INTERPRETED BY

Maggie Machen
Lamy, DVM
DACVIM (Cardiology)

IMAGING PERFORMED BY

Pamela Harrigan,
RDCS

HOSPITAL NAME

Falmouth Animal
Hospital

2-Dimensional Measurements

Ao diam (cm)	1.0
LA diam (cm)	2.3
LA:Ao (Swe)	2.3
IVS thickness (cm)	0.50
LVID diastole (cm)	1.8
PW thickness (cm)	0.50
LVID systole (cm)	0.97
FS (%)	43

Doppler Measurements

PV Vmax (m/s)	0.8
AoV Vmax (m/s)	0.95
MR Vmax (m/s)	NA
TR Vmax (m/s)	NA
TR PG (mmHg)	NA

REFERRING VET

Dr. Switzer

INVOICE

25535

DATE

7/25/22

INTERPRETATION OF THE FINDINGS

The finding of severe left atrial enlargement in the face of normal LV wall thickness is most consistent with Unclassified Cardiomyopathy (UCM). Marked left atrial dilation is



PATIENT
 Jerry Altshuler

present, in addition to subtle smoke which raises the risk of a blood clot event. No additional underlying issues are seen.

SPECIES
 Feline

Regardless of categorical classification, this degree of atrial dilation in addition to pericardial and pleural effusion reflects early congestive heart failure, and immediate lifelong medications are warranted as below. The long-term prognosis is guarded to poor even with medications and no reported symptoms; however, most cats are able to maintain a good quality of life for some time. There will always remain risk for progression to CHF and development of blood clots in the future. The development of VPC's is concerning, and sudden death is certainly possible in the future. Monitoring is certainly advised; particularly should any collapse or significant lethargy be noted in the future.

BREED
 DSH

SEX

Male Neutered

As a complicating factor, there is also a significant ventricular arrhythmia present. Frequent VPCs with periods of bigeminy are diagnosed, No sustained arrhythmias are documented, however this cat is at high risk for development of VT and potentially VF leading to sudden death at any time. My hope is that these arrhythmias are exacerbated by the current crisis and will improve without specific anti-arrhythmic therapy following stabilization. Anti-arrhythmic are often difficult to use in cats; however, follow up is certainly advised.

AGE

14 years

WEIGHT

18lbs

RECOMMENDATIONS

- If patient appears or becomes unstable, consider hospitalization.
- Institute Lasix 1-2mg/kg PO q12h.
- Institute pimobendan off label use 1.25mg PO q12h.
- Institute Plavix 18.75mg PO q24h (NOTE: Medication is bitter along the cut edge; coat in entirety).
- Recheck renal panel, BP and ECG in 5-7 days post-stabilization. Do not utilize ACEI until the patient is doing well at home and BP is >130mmHg.
- If frequent VPCs persists, a low dose of Atenolol can be considered; however, a full ECG evaluation is recommended.
- Monitor for any clinical evidence of cardiac compromise, including respiratory changes and/or signs of a blood clot event (paralysis, neurologic changes, etc.).
- **Elective anesthesia, fluid or steroid therapy are contra-indicated in this patient.**

INTERPRETED BY

Maggie Machen
 Lamy, DVM
 DACVIM (Cardiology)

IMAGING PERFORMED BY

Pamela Harrigan,
 RDCS

HOSPITAL NAME

Falmouth Animal
 Hospital

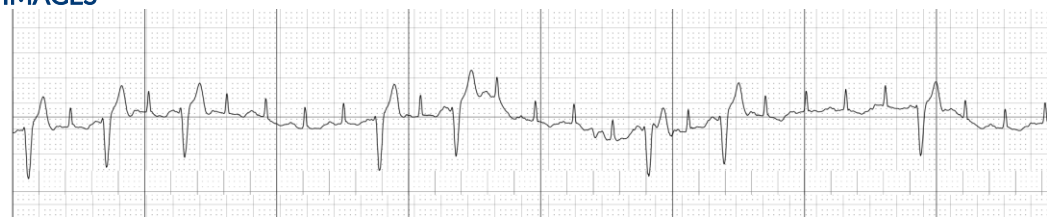
PLAN

- Recommend recheck echocardiogram in 6 months to screen for progressive issues.

REFERRING VET

Dr. Switzer

IMAGES

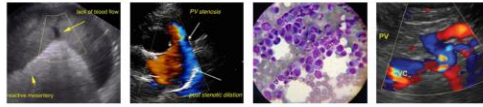


INVOICE

25535

DATE

7/25/22



PATIENT

Jerry Altshuler

SPECIES

Feline

BREED

DSH

SEX

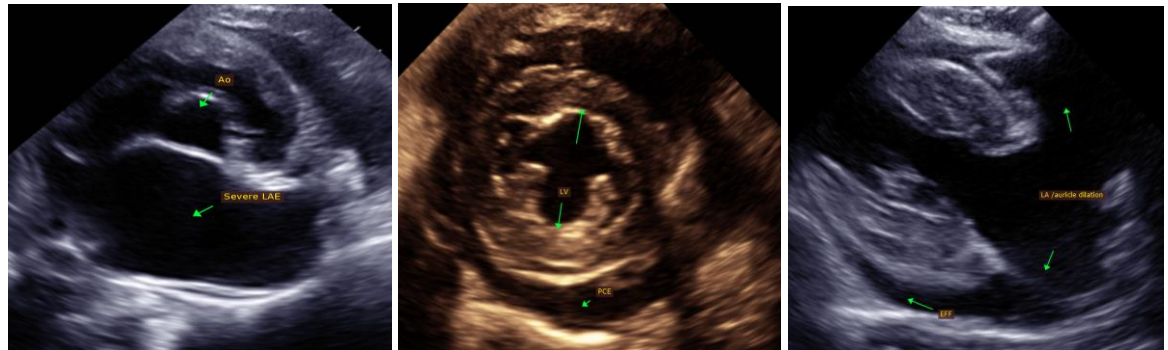
Male Neutered

AGE

14 years

WEIGHT

18lbs



The information and recommendations provided are based on the images presented by the referring veterinarian. No evaluation can be communicated regarding pathology that was not visible in the image/video clips provided.

Thank you for this referral. This report was generated using transcription software, and minor dictation errors may be present. If the clinical or image interpretation does not parallel your findings or if I can be of any further assistance, please contact me.

Maggie Machen Lamy, DVM
 Diplomate of the American College of Veterinary Internal Medicine (Cardiology)
 info@sonopath.com

INTERPRETED BY

Maggie Machen
 Lamy, DVM
 DACVIM (Cardiology)

IMAGING PERFORMED BY

Pamela Harrigan,
 RDMS

HOSPITAL NAME

Falmouth Animal
 Hospital

REFERRING VET

Dr. Switzer

INVOICE

25535

DATE

7/25/22